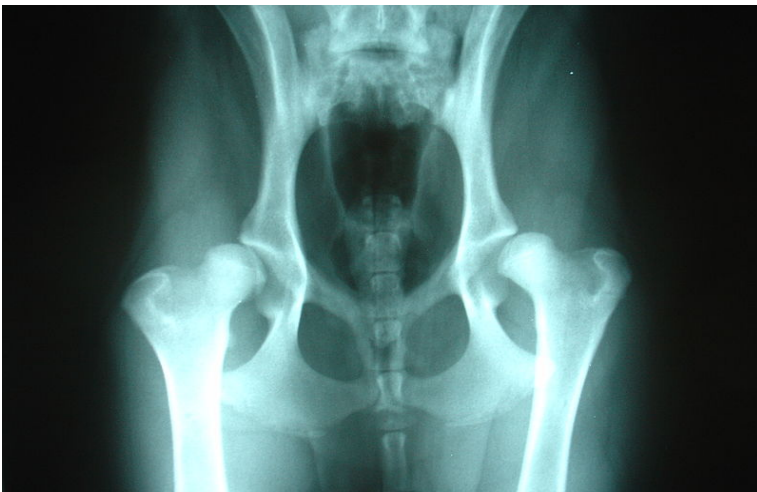
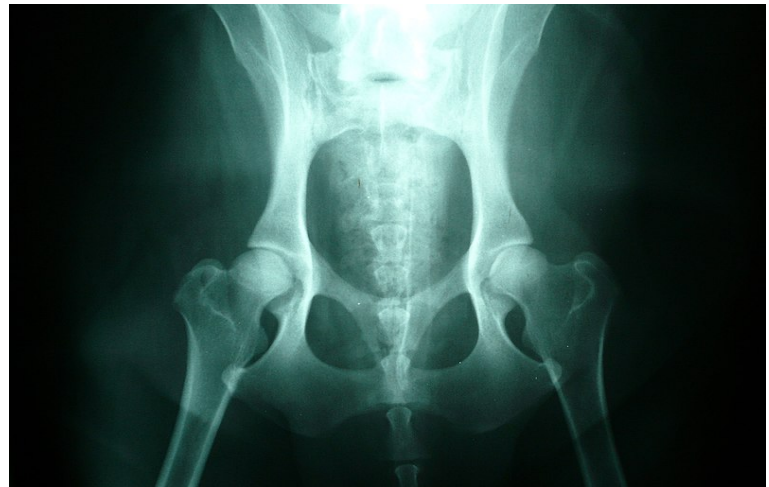

Committed to delivering gold standard accredited Hydrotherapy training and support to the animal rehabilitation industry

Understanding Canine Hip Dysplasia and its Management



Radiograph of bilateral hip dysplasia in a labrador retriever puppy with left hip worse than the right. Joel Mills 2006.



Radiograph of normal dog hips. Joel Mills 2007.

Definition:

'Abnormal development of the coxofemoral (hip) joint characterised by luxation (dislocation) or subluxation of the femoral head in younger patients and mild to severe DJD (Degenerative Joint Disease) in older patients'

Causes:

- Cause is multifactorial
- Hereditary, environmental and nutritional factors play a part
- Hereditary factors are the primary determining factor (20-60%)
- Rapid weight gain and growth through excessive nutritional intake causes disparity of development of the supporting soft tissue
- Factors causing synovial inflammation may also be important

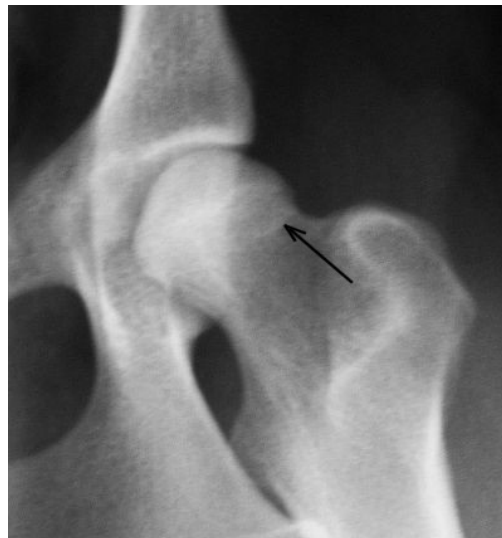Understanding Canine Hip Dysplasia and its Management

- The factors above lead to hip joint laxity and subsequent subluxation is responsible for early changes in the joint and associated clinical signs.
- Subluxation stretches the joint capsule causing pain and lameness and acetabular bone deformity.

- The physiological response to joint laxity is thickening of the joint capsule and increase bone thickness

Clinical Signs:

- Exercise intolerance
- Difficulty rising after rest
- Intermittent/continuous lameness
- Hypotrophy of the pelvic musculature
- Waddling gait
- Sudden worsening during or after increased activity/injury



Radiograph of left canine hip with hip dysplasia. Uwe Gille 2005.

Understanding Canine Hip Dysplasia and its Management

British Veterinary Association (BVA)/Kennel Club Hip Dysplasia Scheme:

- Hip scoring is performed in dogs at, or over, the age of twelve months.
- Radiographs are taken with the dog under general anaesthetic.
- Positioning has to be accurate in order to achieve a satisfactory radiograph for submission to the BVA.
- The British Veterinary Association (BVA) score the hips by measurement and examination of the radiograph.
- Each hip is scored from 0-54 giving a total maximum score of 108.
- Lower the score the better the hips.
- Each breed has an allocated 'mean' score range/average which provides guidance to prospective breeders.
- Only individuals with scores below the breed average should be used for breeding.

Management:

| Common types of Management: | | Immature: | Adult: |
|-----------------------------|--------------------------------|-----------|--------|
| Non-surgical | Conservative | √ | √ |
| Surgical | Pubic Symphysiodesis | √ | X |
| | Total Hip Replacement | X | √ |
| | Femoral Head and Neck Excision | √ | √ |
| | Darthroplasty | √ | √ |

Surgical treatment: pubic symphysiodesis

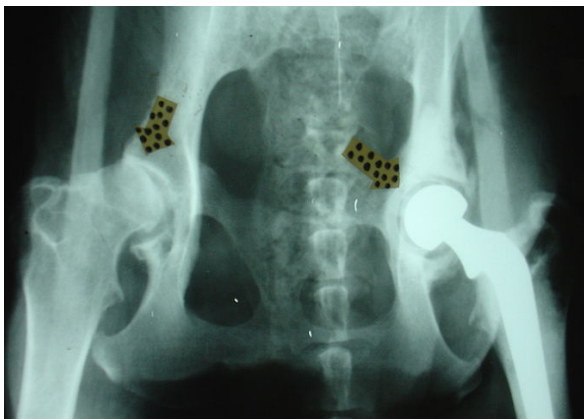
Understanding Canine Hip Dysplasia and its Management

Used in young puppies (<15 weeks old) considered to be at risk of developing hip dysplasia.

- Electrocautery is used to destroy part of the pubic symphysis
- Causes ventroversion of the acetabulum
- Results in increased femoral head coverage
- Causes a narrow pelvic inlet, so neutering is recommended
- At this age, puppies often do not show signs of hip dysplasia, so require a screening test such as Penn Hip.

Surgical treatment: total hip replacement

- Very expensive specialist orthopaedic surgery
- Ideally for medium to large breed dogs
- Must be skeletally mature (>10 months old)
- A polyethylene acetabular cup and metal (cobalt chrome) femoral head and neck are used to replace the existing joint
- Care needs to be taken following surgery as the implant can loosen, luxate, or cause the surrounding bone to fracture
- There is a 95% success rate using the biomedtrix BFX/CFX implants



Radiograph of left hip replacement. The right hip has hip dysplasia with osteoarthritis and remodeling of the head of the femur. Joel Mills 2006.

Surgical treatment: Femoral Head and Neck Excision Osteotomy

- Or excision arthroplasty or femoral excision osteotomy
- This is where the femoral head and neck are removed
- Relieves the pain from a previously 'grinding' joint
- Allows a fibrous joint to form

Understanding Canine Hip Dysplasia and its Management

- Usually for dogs (and cats) < 15-20kg

Surgical treatment: DArthroplasty

- Uses a corticocancellous bone graft (usually the ilial wing) to extend the dorsal acetabular rim (DAR)
- Creating a 'shelf'
- The graft is sutured to the adjacent joint capsule
- This provides support through joint capsule hypertrophy rather than bony fusion
- This method still remains largely unproven

Conservative Management Options:

- Weight management – important
- Nutritional supplementation
- Exercise
- Anti-inflammatory drugs
- Physical rehabilitation

Weight management

- Prevent excessive weight gain in puppies
- Restricting food intake in growing dogs has been reported to be beneficial
- Maintain at or slightly below normal body weight in adults
- Weight reduction has been shown to significantly improve lameness in adult dogs

Nutritional supplementation

- Nutraceutical and chondroprotective drugs
- Slow acting, disease modifying agents
- May help control associated osteoarthritis
- Abundant anecdotal evidence about their beneficial effects
- No controlled studies have yet to show any benefit(s)

Exercise

Understanding Canine Hip Dysplasia and its Management

- Appropriate level of exercise to maintain muscle development and fitness
- Needs to meet with owner's lifestyle expectations without exacerbating clinical signs
- Regular low impact exercise is preferable to intermittent, forced or high impact activities (i.e. chasing balls)
- Hydrotherapeutic exercises can be hugely beneficial

Anti-inflammatories/pain control

- Should be regularly assessed
- Dogs may not require continuous medication
- Doses should be reduced if possible, under the instruction of a veterinary surgeon
- Dogs with osteoarthritis will have occasional 'flare ups' which will require additional short term control

Drug types

- Non-steroidal anti-inflammatory drugs (nsaids), e.g. Metacam/Previcox
- Steroids, e.g. Prednisolone/PLT
- Opiates, e.g. Tramadol
- NMDA antagonists, e.g. Amantadine
- GABA analogue, e.g. Gabapentin

Physical rehabilitation

-



Understanding Canine Hip Dysplasia and its Management

Hydrotherapy - pool and aquatic treadmill therapies

- Provides a means of safe, effective and controlled exercise opportunities for dogs
- Studies show swimming or walking in water produces greater joint flexion but less extension compared with walking on dry land

Connect with us.....

info@hawksmoorhydrotherapy.com

www.hawksmoorhydrotherapy.com

www.facebook.com/hawksmoorhydrotherapy

www.twitter.com/HawksmoorHydro

www.instagram.com/hawksmoorhydro